

Clinical News Corner

Focusing on current and new clinical procedures *An Andramed Publication*

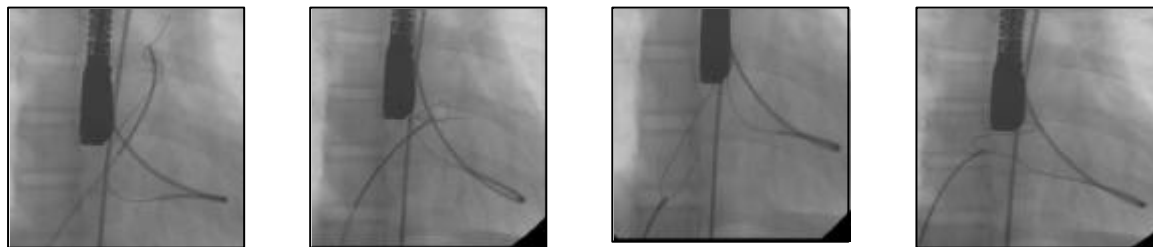
Case Report: Paediatric Cardiology VSD Wire Pull-Through Technique With The AndraSnare And Retrieval Of Occlusion Device

References: Dr. William Torres, Ascardio-Venezuela

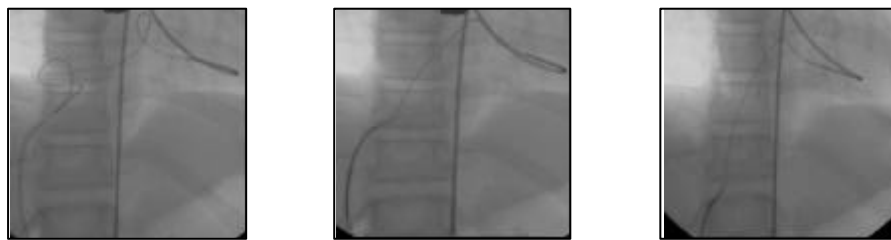Positioning of a VSD Occluder Device under Flouro and TEE with the Wire Pull-Through Technique and use of the **AndraSnare** .

The **AndraSnare** by Andramed is an excellent Snare device for this kind of procedure. The increased torque-ability and visibility plus increased technical features make the AndraSnare the device of choice for 3Dimensional capturing. A **AndraSnare AS20** (20mm) was used in the primary two steps. Catch the Wire to perform the pull-through into the pulmonary artery than to snare wire in the right atrium. The procedure demonstrated the ease of use of the AndraSnare.

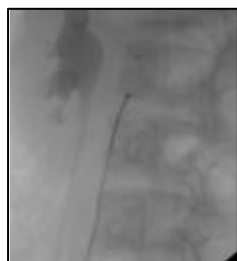A **AndraSnare AS5** (5mm) was than used to retrieve a Amplatzer device of muscular VSD after it embolized into the abdominal aorta. It could be safely extracted through the femoral artery.



1,2,3,4: Taking wire into pulmonary artery with big snare and putting in right atrium, real 3D capturability



5,6,7: Using 20mm snare to fish wire again into right atrium without any problem



8: Snaring an Amplatzer device of muscular VSD with a AS5 AndraSnare (5mm) after embolization into abdominal aorta



Andramed GmbH
Silvanerstr. 8
D-72766 Reutlingen
ph: +49(0)7127 972290
Fax: +49(0)7127 972291
www.andramed.com